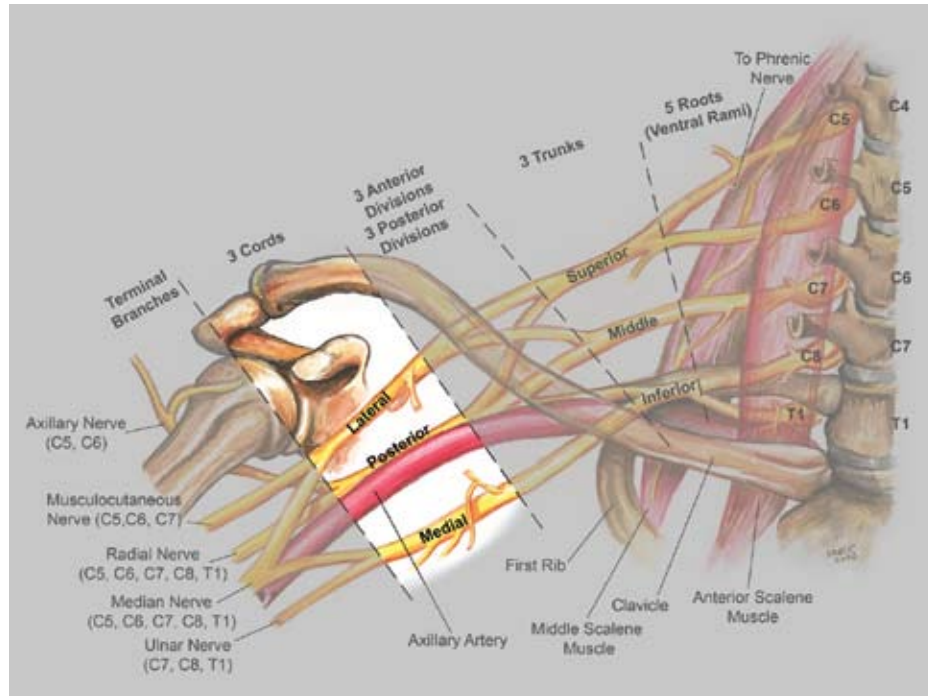


9. INFRACLAVICULAR BLOCK

INTRODUCTION

The infraclavicular brachial plexus block is ideal for operations distal to the elbow. Adequate time (approximately 20 minutes) should be allowed after the block placement to achieve a surgical level of anesthesia. Although there are multiple approaches to the infraclavicular block, success depends on where the needle tip stimulates the plexus. Caution must be taken to ensure that the needle tip is maintained within the infraclavicular fossa at the level of the cords and not directed distally toward the terminal branches located in the axilla. The latter erroneous position usually results from excessive angulation of the needle toward the axilla and may result in inadequate blockade of the musculocutaneous and axillary nerves.

Figure 9-1



ANATOMY

The infraclavicular block is performed at the level of the cords of the brachial plexus. The cords are named according to their relation to the axillary artery: lateral, medial, and posterior. The lateral cord is formed from the anterior divisions of the superior and middle trunks, the medial cord is formed from the anterior division of the inferior trunk, and the posterior cord is formed from the posterior divisions of all three trunks. The plexus, which begins to spread around the axillary artery at this level, is not as compact as the more proximal trunks (Figures 9-1 through 9-3). Therefore, this block typically has a longer latency, and may not be as dense, as a supraclavicular nerve block.

Compared to the supraclavicular block, an advantage of the infraclavicular block is the reduced possibility of pneumothorax and avoidance of cervical vascular structures. This block does not produce a reduction in respiratory function. Additionally, the infraclavicular block has been shown to be superior to the axillary nerve block for anesthetizing the axillary and musculocutaneous nerves, making a supplemental musculocutaneous nerve block unnecessary.

Acceptable muscle stimulation patterns are either extension (radial nerve) or flexion (median nerve) of the digits. A biceps twitch (musculocutaneous nerve), suggests that the needle placement is too lateral. The axillary vessels can be punctured using this approach, and vessel compression in this area is difficult.

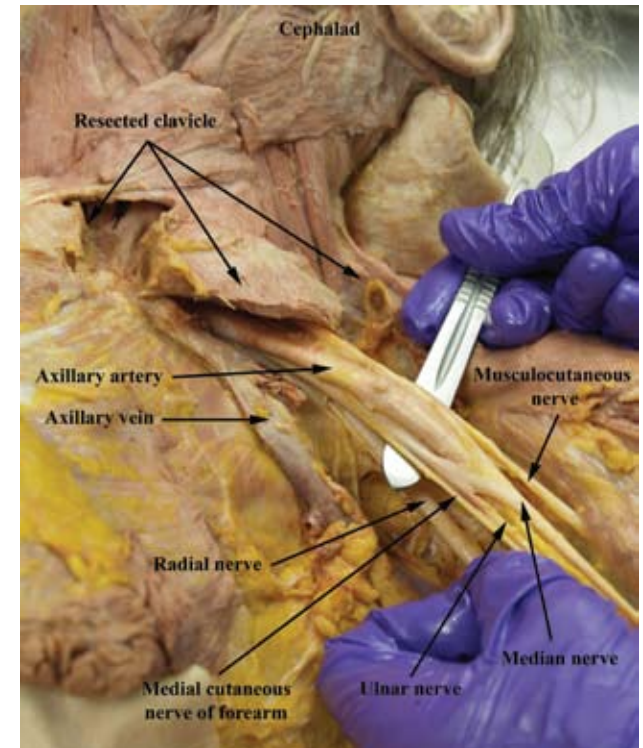
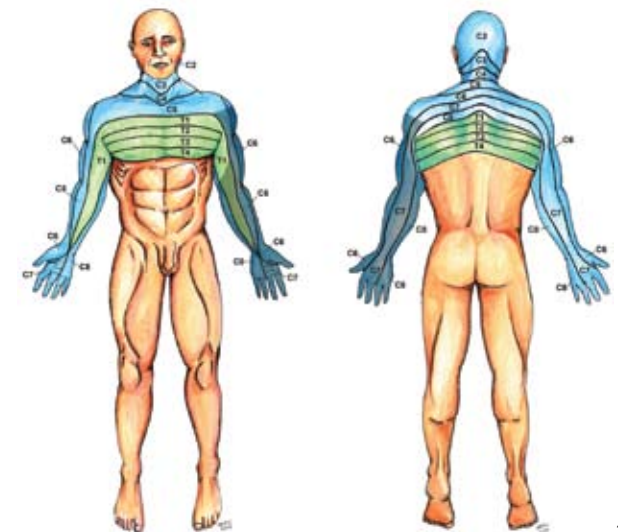


Figure 9-2

Figure 9-3. Dermatomes anesthetized with the infraclavicular block (dark blue)



PROCEDURE

Landmarks. Externally rotate and abduct the operative arm. Palpate the coracoid process. Make a mark 2 cm medial and 2 cm caudad from the coracoid process (Figure 9-4). This is the insertion point. Palpate the axillary artery as proximal as possible in the axilla. This is the direction of initial insertion. Insert the needle at an approximately 60° angle from the horizontal (Figure 9-5).

Needles

- 21-gauge, 10-cm, insulated needle.

- 18-gauge, 10-cm, insulated Tuohy needle for catheter placement. Catheters inserted 3 cm.

Stimulation. The nerve stimulator is initially set between 1.0 and 1.2 mA. Finger and/or thumb flexion at 0.5 mA or less indicates adequate needle placement for local anesthetic injection. Finger extension with stimulation is also acceptable. Stimulation of the musculocutaneous nerve indicates that the needle is too lateral.

Local Anesthetic. In most adults, 30 to 40 mL of local anesthetic will block the plexus at this level.

ALTERNATIVE APPROACH

A simple alternative to the coracoid approach is the deltopectoral groove approach (see Figure 9-5). With the patient's arm at his or her side, mark the base of the clavicle and palpate the deltopectoral groove from the axilla up to the clavicle. At approximately 1 cm below the clavicle, place the needle in the deltopectoral groove (perpendicular to the bed), and then redirect it 10° toward the axilla. Advance the needle until the plexus is encountered. Compared to the coracoid approach, this approach will block the plexus at a more proximal location, which is desirable because the plexus is more compact and easier to block proximal.

Figure 9-4

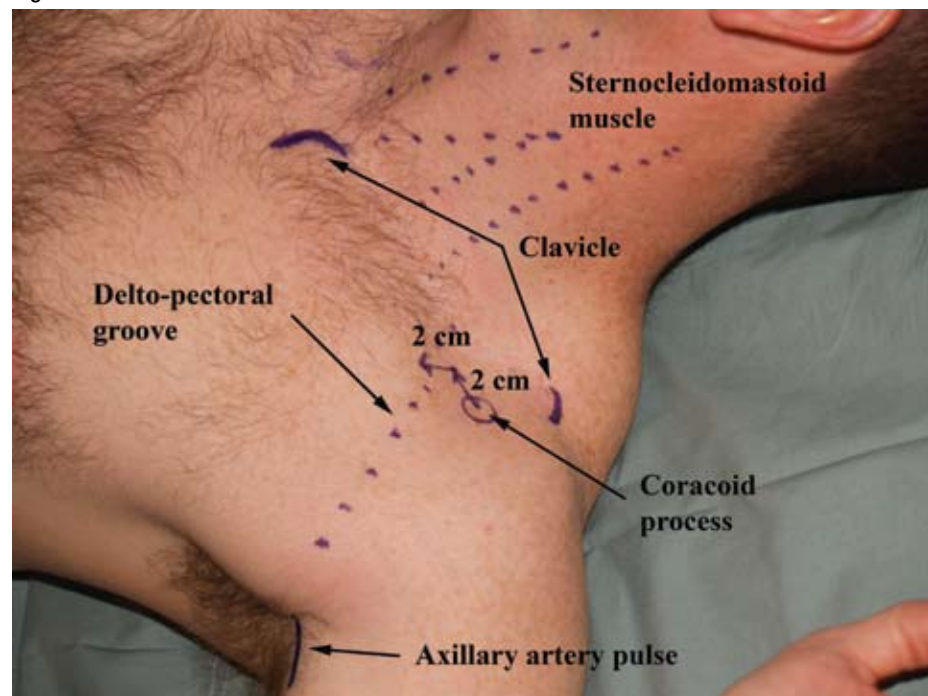
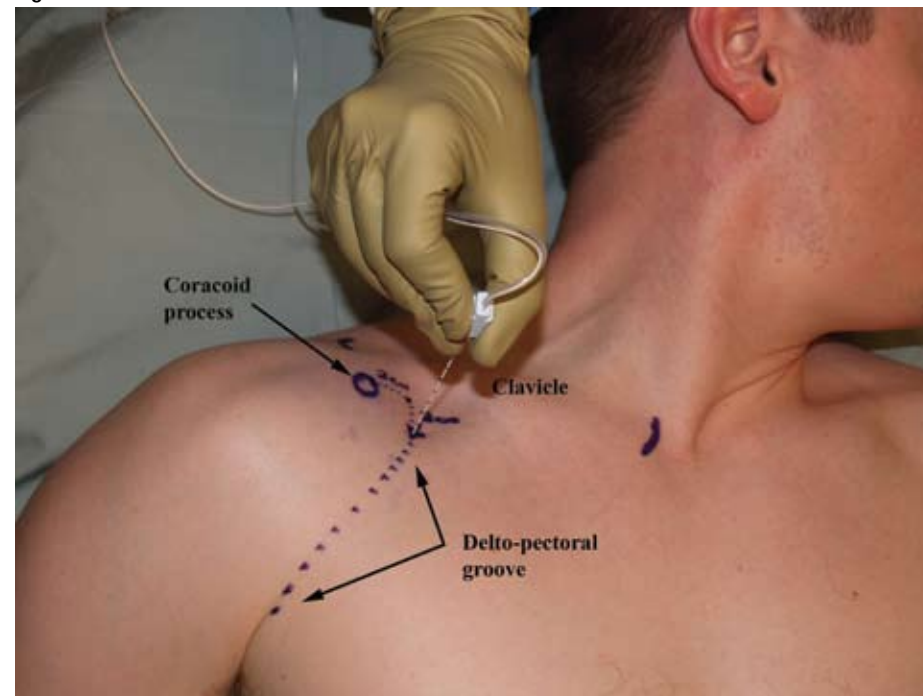


Figure 9-5



BLOCK WITH ULTRASOUND PROBE

Probe. High frequency (5–12 MHz), linear.

Probe Position. The parasagittal plane gives the best transverse view of the brachial plexus; below the level of the clavicle, the nerves appear hyperechoic. Position the probe beneath the clavicle and medial to the coracoid process (Figure 9-6).

Approach. The needle is typically inserted in-plane at the cephalad (lateral) aspect of the probe, and will be visualized at the lateral border of the axillary artery. The hyperechoic structure lateral to the artery is the lateral cord; the needle should pass lateral to this cord and progress farther to the posterior cord. The posterior cord is the hyperechoic structure located at the base of the axillary artery (Figure 9-7). Recent evidence suggests that deposition of local anesthetic around the posterior cord will result in improved block success.

Another approach to the posterior cord is via the inferior aspect of the probe (still in the parasagittal plane). With this technique, the needle is visualized at the medial border of the axillary artery, and between the axillary artery and vein. The needle must travel along the lateral aspect of the medial cord to reach the posterior cord. This approach is technically more difficult because of the close proximity of the axillary artery to the needle path; however, it allows catheters to be threaded with less difficulty.

Injection. It is important to observe the spread of the local anesthetic during the injection, which allows readjustment of the needle position if the spread is not appropriate. Spread should appear around the posterior cord; any spread above the artery in the area of the pectoralis muscles will likely result in block failure (Figure 9-8).

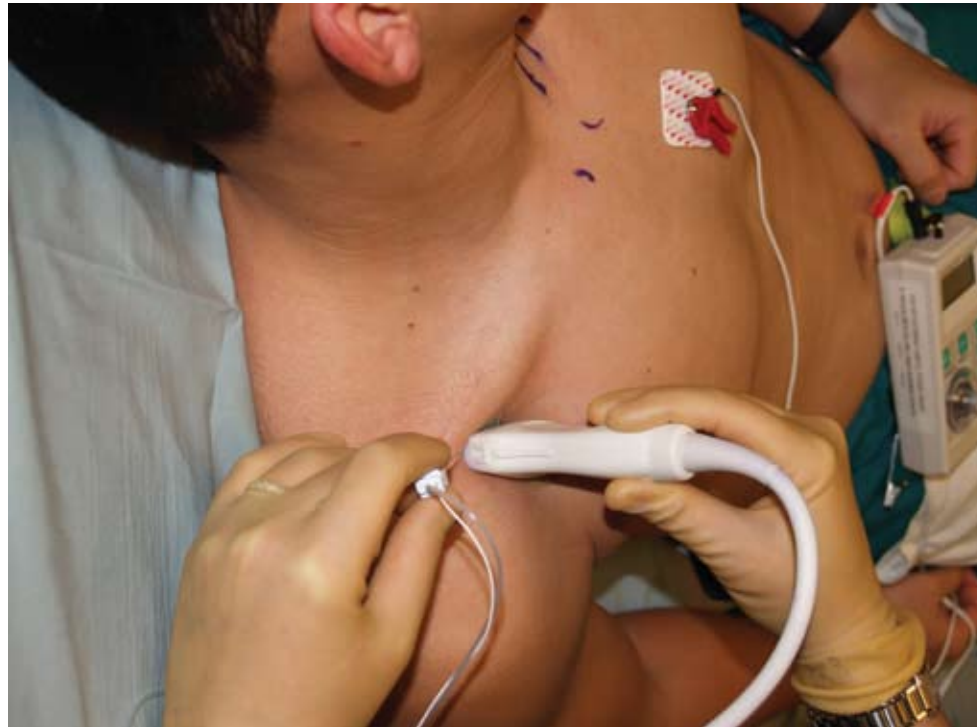

Figure 9-6

Teaching Points. As with the nerve stimulator technique, care must be taken to avoid vascular puncture because compression for bleeding in this area can be difficult. Always keep the axillary artery and vein in view during needle guidance, and always ensure that the full length of the needle to the tip in the longitudinal (in-plane) view is clear.

Figure 9-7

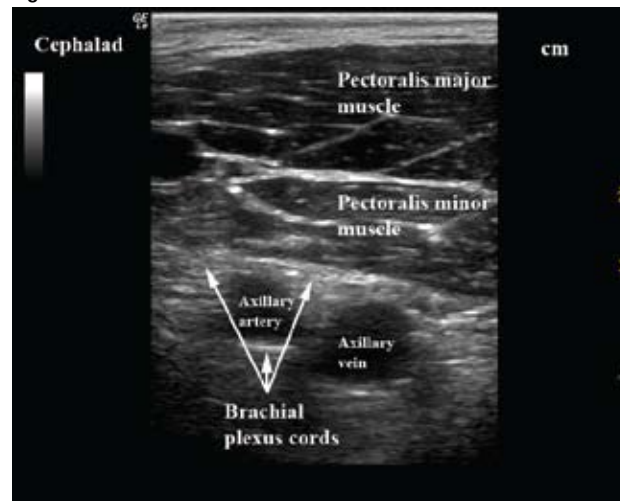


Figure 9-8

